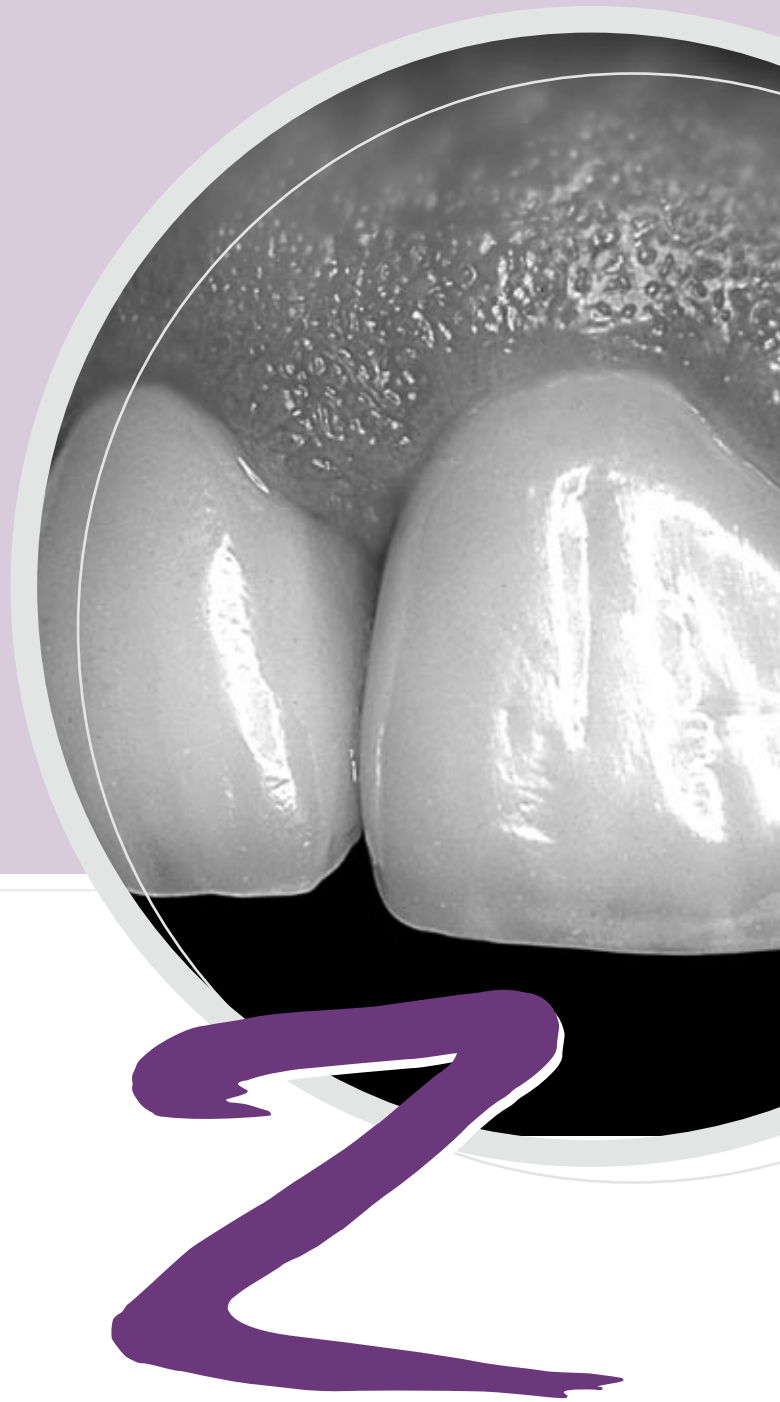

Preparation guide



The Material

- Zirconium oxide has a proven track record of over ten years as a high-strength framework material for dental restorations. With a bending strength of > 1000 MPa, this is the first material that can also be used to make long-span bridgework for posteriors. The occlusion can be checked during try-in, whilst both temporary cements and conventional permanent cements can be used, thus simplifying treatment considerably.

Full ceramic crowns on a ZENO® framework offer excellent aesthetics (Figs. 1, 2 and 3), since zirconium oxide is a white, translucent material which can be stained to resemble natural dentine. Its low plaque affinity and low coefficient of thermal expansion make this biocompatible material the ideal framework material for prosthetic restorations.

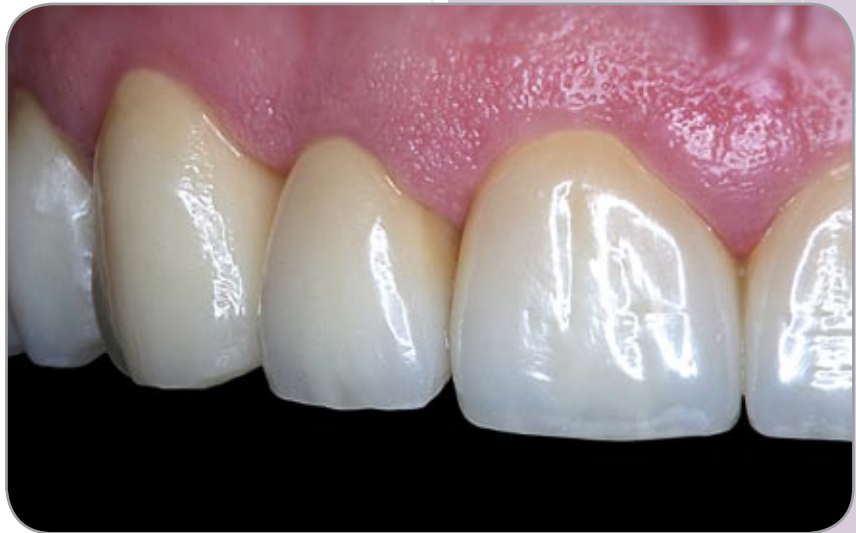

Fig. 1
Aesthetically pleasing ZENO® anterior crowns; made by Master Dental Technician F. Wüstefeld, Hanover

Indications

- As a matter of course, the ZENO® Tec system can be used to fabricate partial crowns, crowns and bridges for both anterior and posterior regions.

Contraindications include a lack of space in the bridge connector area, since connectors must have a generous cross-section.

If the patient suffers from bruxism, the practitioner must decide on a case by case basis whether a full ceramic restoration is suitable or whether a metal occlusal surface is preferable.

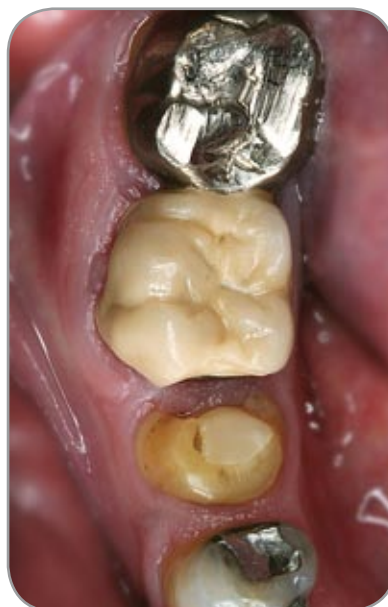

Fig. 2
Before: Inadequate restoration in the posterior region

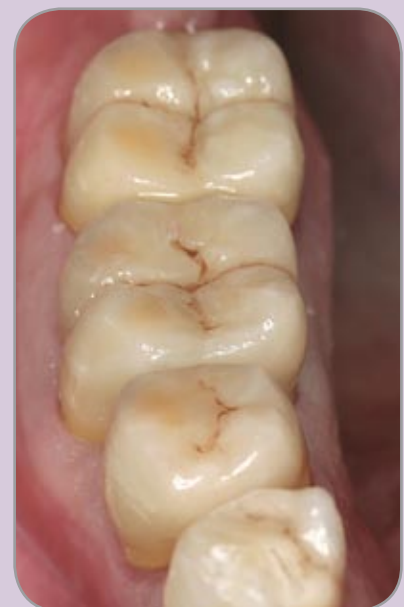
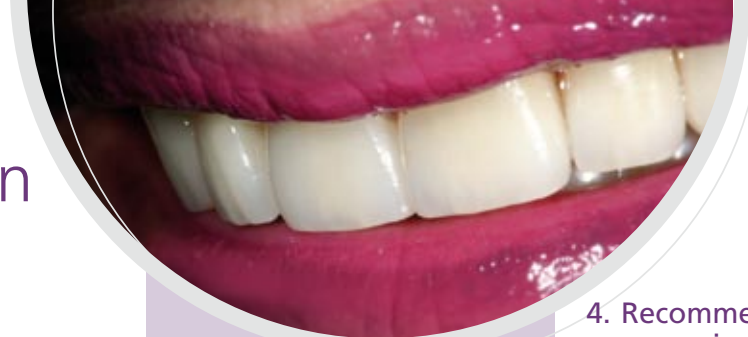
Fig. 3
After: ZENO® crowns in situ

Preparation



1. First steps

- Before starting treatment (and prior to administering an anaesthetic), use an ultra thin articulating film to record the bite whilst the patient is still seated upright. This enables the occlusion to be verified on articulated models at a later stage.

2. Existing root canal pins

- Since it is a relatively opaque material, zirconium oxide can be used to completely cover existing pin restorations. This therefore also enables intact pin superstructures, which are often very difficult to remove, to remain in place when the tooth is prepared.

In the case of highly aesthetic anterior crowns with a slender framework having a wall thickness of 0.4 mm, it is advisable to coat any existing metal pin with a tooth-coloured composite or to increase the wall thickness in order to increase the opacity of the framework.

Ideally, a new pin should be inserted and bonded to the dentine. For this purpose, composite pins reinforced with fibreglass have proven to be suitable, since they possess an elasticity and appearance similar to that of natural dentine.

3. Reconstruction material

- For small defects, reinforced glass ionomer cements can be used as a low-cost filling material. Larger defects should be restored with composite materials bonded to the dentine. Compomers are unsuitable for this purpose, since they expand through swelling and can therefore exert undue pressure on the ceramic.

4. Recommendations for preparing a tooth for a ceramic restoration

- The preferred instruments are the established abrasive burs from the zirconium oxide preparation set according to Dr. H. v. Blanckenburg, Gebr. Brasseler (Fig. 4a). Equally suitable is the zirconium oxide preparation set according to Dr. Beuer (Fig. 4b).

In general, a tooth prepared for a zirconium oxide restoration must always have a reduced anatomical shape with rounded edges. This enables the technician to design a framework, which is supported by cusps and has an even layer thickness. The thicknesses required for the subsequent restoration are similar to those specified for PFM restorations. There is no truth in the rumour that full ceramic restorations always require a greater reduction of hard tooth substance.

For anteriors, a thickness of 0.4 mm is adequate for a single zirconium oxide coping. For posterior crowns and for bridge anchors a thickness of 0.5 mm to 0.6 mm should be allowed for. The veneer then requires a further 1.0 to 2.0 mm at the occlusal/incisal surfaces (the same as for PFM restorations).

The prepared tooth should be tapered with a side angle of about 4°. This gives the best scanning results in the lab and ensures that the crown is sufficiently anchored to the tooth.

The largest circumference of the prepared tooth is clearly visible in the area of the gingival preparation margin. It does not matter here whether the preparation has a distinct chamfer or is a shoulder with a rounded inner edge. At the margins the cut should be circular with a uniform depth of 1.0 mm.



Fig. 4a
Ergonomic preparation set according to Dr. H. v. Blanckenburg



Fig. 4b
ZENO® Preparation set according to Dr. Beuer

5. Efficient preparation – step-by-step

Tip: An epigingival preparation simplifies every step of the procedure, right up to the fitting.

■ Step 1:

Use a coarse diamond bur to reduce the axial tooth surface (Figs. 5 and 6). In doing so, a chamfer with a depth of 1 mm should be formed in a single pass.

Tip! An accentuated preparation margin in its final position serves as a guide for the final stages of the preparation. This initial shoulder and chamfer will subsequently guide the instrument smoothly, even in less accessible areas.

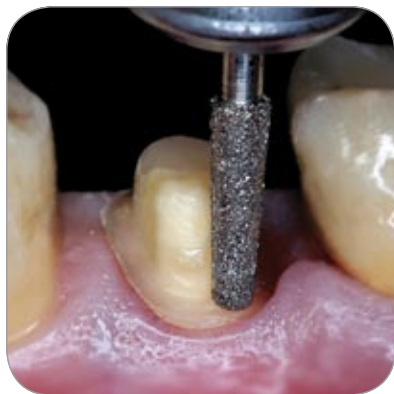

Fig. 5
Step 1: Initial preparation using a coarse diamond bur for the posterior region

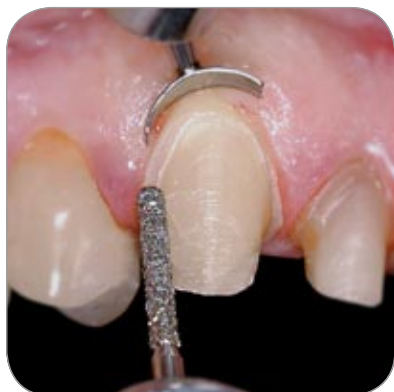

Fig. 6
Step 1: A thinner instrument for the anterior region; an accentuated chamfer makes all subsequent steps easier

■ Step 2:

Create an anatomical cusp-supported shape for the occlusal relief/reduce the lingual concavity of incisors (Figs. 7 and 8).

Tip! Ensure that there is adequate space (Fig. 9). Verify this by using bite registration wax or a silicone impression.

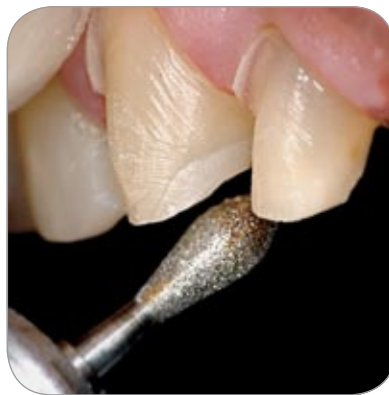

Fig. 7
Step 2: Removal of lingual hard substance from anteriors

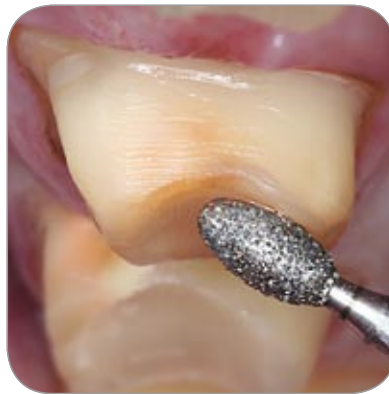

Fig. 8
Step 2: Removal of occlusal hard substance from molars

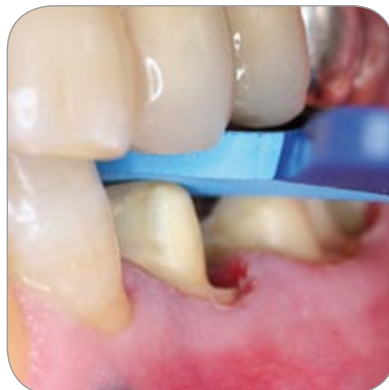

Fig. 9
Checking the space created by means of a bit registration

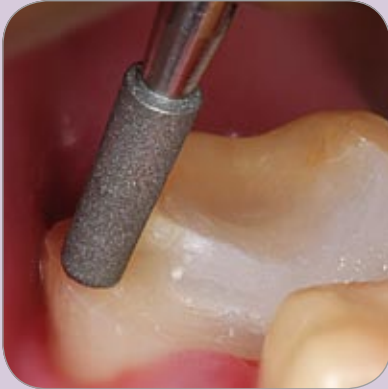

Fig. 10
Step 3: Short finishing bur for partial crowns and less accessible areas

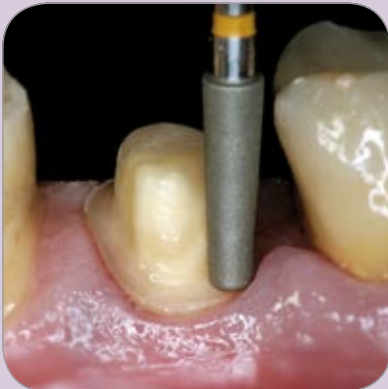

Fig. 11
Step 3: Tapered diamond finishing bur for molars

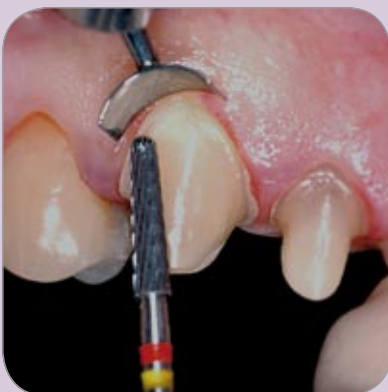

Fig. 12
Step 3: Special carbide finishing bur; an ergonomic instrument for anterior and posterior regions

■ **Step 3:**

Complete the preparation with a gently tapered diamond finishing bur (Figs. 10 and 11) or with a special tapered carbide finishing bur used at a lower speed (Fig. 12).

The different toothing on the shaft and tip of this universal instrument means that the shoulder can be formed smoothly and without trauma in a single pass and the tooth walls can be smoothed to a defined degree of gentle roughness. The finely toothed tip runs very gently and evenly over the shoulder shaped during the initial stage of the preparation. This atraumatic instrument does not damage the gingiva, but the shaft creates a surface structure which is ideal for retaining the crown.

Tip! Tilt the tapered instrument gently towards the outside. If a channel was formed during the initial preparation, it is now easy to smooth over (Fig. 13). In special cases it is also possible to use a ceramic abrasive specially trimmed with a diamond abrasive (Fig. 14, 15).

■ **Step 4:**

Now round all edges with finishers or ceramic burs (Fig. 16). Since zirconium oxide restorations can nowadays only be made by machining industrially produced blanks, this must be taken into consideration during preparation. For example, no sharp edges must remain after preparation, especially in the anterior region.

Note: Do not polish the prepared tooth.

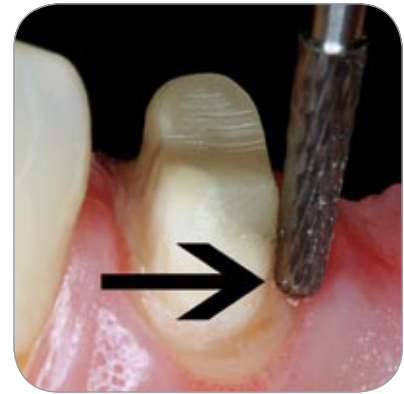

Fig. 13
Extremely safe and atraumatic finishing of the accentuated chamfer

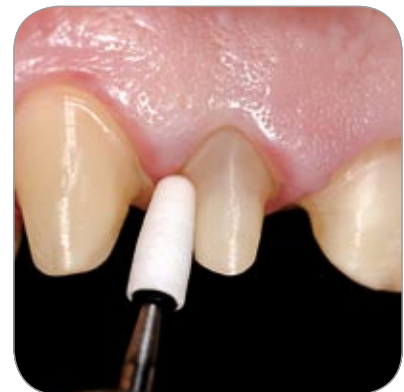

Fig. 14
For special cases a ceramic abrasive is customised with a diamond abrasive



Fig. 15
Finishing the preparation and rounding all edges

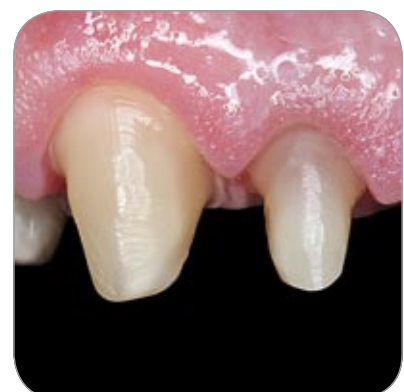

Fig. 16
The finished preparation

Impression taking

■ Impressions for zirconium oxide restorations must be taken using a precision impression material (Figs. 17 and 18). One method of exposing the prepared margin and retracting the gingiva before the impression is taken is the use of non-impregnated retraction threads. For this, the so-called "V" technique is a well-proven method. First, a No. 1 retraction thread is placed around the entire sulcus of the prepared tooth and then a thicker thread is placed on top of this. Both threads are left in the sulcus for 10 minutes. Then the thicker thread is removed. Provided that there is no bleeding and that the entire margin is visible, the impression can now be taken.

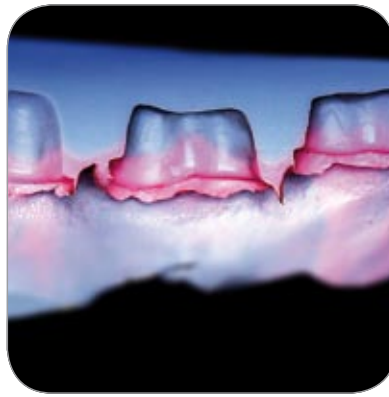


Fig. 17
Cross-section of a (hydrocolloid) impression

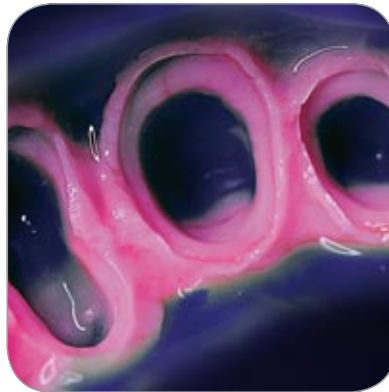

Fig. 18
Impression: all contours are clearly visible

As an alternative or in addition to the use of threads, electrotomy or laser techniques can also be used to expose the prepared margin, whereby all forms of retraction must be as gentle as possible, especially in areas where the gingiva is visible. With the electrotomy method it is advisable to use the thinnest instrument available to open the sulcus. The subsequent impression should be taken using customised or individual impression trays.

The preferred impression material is polyether using the one-off single-phase technique or hydrocolloid. After removing the tray from the mouth, examine the impression under a stereo microscope or through magnifying glasses. Repeat the procedure if necessary. The quality of the impression is the dentist's visiting card.

Temporary restorations

■ The best way to make a matrix for a temporary restoration in the dental laboratory is by vacuum forming a polyethylene laminate over an independently made model of the original dentition. The thickness of the layers allowed for by the preparation can be checked before the impression is taken by placing the clear matrix in the mouth and observing the amount of tooth substance that has been removed. With bridgework, an artificial tooth can be inserted into the model and then integrated into the temporary restoration to achieve perfect results. The temporary bridge also acts as a splint and prevents the abutment teeth from straying.

To check the hardness, first dispense a pea-sized reference sample onto the treatment tray, then fill the matrix with auto polymer and position it in the mouth over the abutment teeth and pontics and ask the patient to close their mouth. The reference sample on the treatment tray

helps you to determine when the acrylic material passes from the soft plastic stage to the heat-emitting polymerization phase. Shortly after this transformation stage, remove the matrix from the mouth and place it in a water bath heated to 50° C in order to accelerate the curing process. Now remove the temporary restoration from the polyethylene matrix and trim. If possible, the final trimming should be carried out on a polishing lathe in the dental laboratory. After buffing with pumice, insert the temporary restoration in the patient's mouth once more, check the static and dynamic occlusions, correct as necessary and double-check the edge margins and the approximal contact points.

With the ZENO® Tec System it is also possible for the technician to make a long-lasting temporary crown from PMMA on the CAD/CAM system within a few hours (Fig. 19).

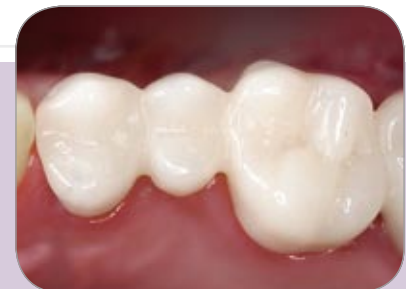

Fig. 19
Temporary restoration

Tip! For anteriors, shorten the temporary restoration at the labial surface by approx. 0.5 mm to avoid irritation of the gingiva and prevent recession.

Finally the temporary restoration is lathe polished to a high lustre and fixed onto the prepared teeth with eugenol free cement (Fig. 20)

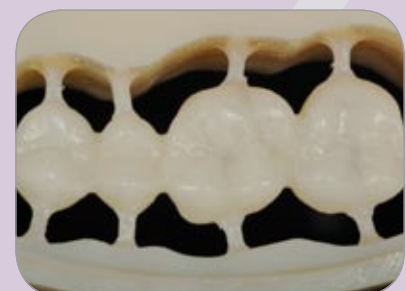

Fig. 20
Temporary restoration made from ZENO® Tec PMMA

Framework try-in optional

■ In special cases, it may be advisable to try in the zirconium oxide framework before completing the restoration. When doing so, check the marginal fit by applying a thin-flowing impression material to the gap between the prepared tooth and the restoration. Then clean the framework with alcohol to ensure that no traces of silicone are left inside the restoration. After the impression material has set, remove the restoration from the mouth. If the marginal fit is a good one, the material will tear off cleanly at the crown margin. At this stage, a refit can be carried out using the zirconium oxide framework as a basis.

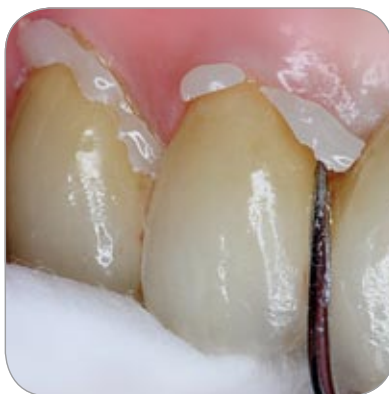

Fig. 21
Cementing with dual cement;
the excess is easy to remove



Fig. 22
High translucence and light transmission
into the sulcus and the gingiva

Fitting

■ When the occlusion, shade and approximal contacts have been checked, the restoration can be fitted into the mouth.

The question of whether to use adhesive or cement continues to be a controversial issue. From a clinical point of view it does not matter whether the cement used is phosphate cement mixed by hand or a glass ionomer cement supplied in a pre-mixed capsule. The restoration can also be fixed by means of autopolymers or dual cements (e.g. RelyX® Unicem, 3M ESPE; Panavia F, KURARAY DENTAL). The translucent material allows light to pass from the restoration to the tooth preparation and through the preparation margin into the root dentine. A paramarginal preparation does not reveal the cement gap (Figs. 21 and 22).

Trephination and removal

■ Although the low thermal conductivity of a zirconium oxide restoration provides excellent insulation for the dental pulp, it may be necessary to carry out endodontic treatment on the restored teeth. In this case, the following procedure must be observed: First use a coarse diamond bur to completely remove the ceramic veneer from the point at which entry is to be made. Only then can the framework of the restoration be penetrated, again using a coarse diamond bur. Hold the bur at an angle of approx. 45° to the zirconium oxide framework,

in other words at a tangent to the tooth. This ensures that the diamond bur is always adequately-cooled and prevents it from overheating (Fig. 23).

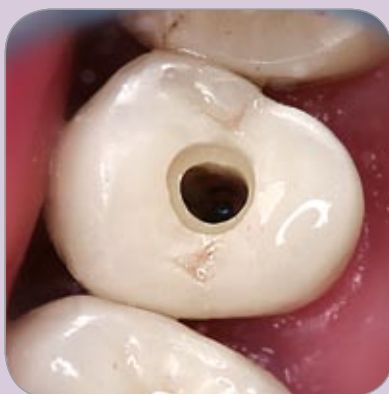

Fig. 23
Trepanation of a ZENO® crown;
use generous water cooling

A similar procedure should be followed when removing a restoration. It may be necessary to remove the ceramic veneer from the approximal regions in order to break up the framework. On the whole it can be said that the trephination or removal of a zirconium oxide restoration is just as straightforward as that of a framework made from a non-precious metal.

Clinical work:
Dr. Hartmut von Blanckenburg

Lab work:
Master Dental Technician
Frank Wüstefeld

**WIELAND Dental + Technik
GmbH & Co. KG**
Schwenninger Straße 13
75179 Pforzheim, Germany

Fon +49 72 31/37 05-0
Fax +49 72 31/35 79 59

www.wieland-international.com
info@wieland-international.com

International Representations

WIELAND Dental+ Technik is worldwide represented. Find your contact person in your country under www.wieland-international.com or call us under telephone number +49 72 31/37 05-0.

WIELAND
Dental Division